



# Understanding the Psychological and Sociological Effects of Molar Incisor Hypomineralization: A Scoping Review of Current Evidence

Tuğba Aydoğdu<sup>ID</sup>, Berkant Sezer<sup>ID</sup>

Department of Pediatric Dentistry, School of Dentistry, Çanakkale Onsekiz Mart University, Çanakkale, Türkiye

Cite this article as: Aydoğdu T, Sezer B. Understanding the psychological and sociological effects of molar incisor hypomineralization: a scoping review of current evidence. *Essent Dent*. 2025, 4, 0050, doi:10.5152/EssentDent.2025.25050.

## Abstract

Molar incisor hypomineralization (MIH) is a dental condition characterized by enamel opacities, discoloration, and structural fragility, which can significantly affect individuals' psychological and sociological well-being. In affected teeth, post-eruptive enamel breakdown often occurs, resulting in structural deficiencies that increase dentin hypersensitivity and hinder effective oral hygiene maintenance. This compromised hygiene can, in turn, elevate the risk of dental caries and periodontal disease, necessitating more frequent dental interventions. Over time, these challenges may contribute to the development of dental anxiety and behavioral management difficulties. Moreover, MIH can lead to functional limitations, such as masticatory difficulties and speech impairments. The impact of MIH extends beyond its physical symptoms, especially during childhood and adolescence, potentially resulting in significant psychosocial consequences. Enamel discoloration and loss of structure may cause aesthetic concerns, reduced self-esteem, and social withdrawal. Given the multifaceted effects of MIH, early diagnosis and individualized treatment strategies are essential for mitigating both its physical and psychosocial burdens, ultimately improving the overall quality of life of affected individuals. This scoping review aims to comprehensively evaluate, based on current scientific evidence, the functional and specific psychosocial impacts of MIH.

**Keywords:** Molar hypomineralization, oral health, pediatric dentistry, psychosocial functioning, quality of life

## INTRODUCTION

Molar incisor hypomineralization (MIH), a developmental enamel defect, was first defined in 2001. It primarily affects 1 or more permanent first molars and, in some cases, permanent incisors, presenting as well-demarcated qualitative enamel defects.<sup>1</sup> Some studies have also reported MIH involvement in permanent canines and second primary molars.<sup>2</sup> Clinically, MIH manifests as well-demarcated opacities, ranging from white/creamy to yellow/brown in mild cases. In more severe cases, the enamel becomes porous, increasing the risk of structural breakdown and early tooth loss.<sup>3</sup>

Although MIH was formally defined in 2001, clinical observations of developmental enamel defects affecting first permanent molars date back to the 1980s. Since then, this condition has received increasing attention and has been extensively investigated through global prevalence studies.<sup>4</sup> Comprehensive literature reviews have identified MIH as a significant global health concern due to its occurrence across diverse populations.<sup>2,5</sup>

Corresponding author: Berkant Sezer  
e-mail: dt.berkantsezer@gmail.com or berkant.sezer@comu.edu.tr



Content of this journal is licensed under a Creative Commons  
Attribution-NonCommercial 4.0 International License.

Received: April 17, 2025  
Revision Requested: May 26, 2025  
Last Revision Received: July 6, 2025  
Accepted: August 11, 2025  
Publication Date: December 31, 2025

Researchers estimate the global prevalence of MIH to be approximately 13.5%, with no statistically significant variation across continents.<sup>2</sup> According to Lopes et al.,<sup>2</sup> approximately 36.3% of MIH cases are classified as moderate to severe, with incisor involvement reported in 36.6% of affected individuals. Moderate MIH typically involves enamel breakdown and hypersensitivity that requires treatment. In contrast, severe MIH is characterized by post-eruptive enamel breakdown, atypical caries, atypical restorations, or tooth extraction due to structural damage.<sup>2</sup> These findings underscore the global importance of MIH in terms of both its widespread distribution and clinical severity.

The etiology of MIH has been attributed to a range of factors occurring during the prenatal, perinatal, and postnatal periods.<sup>3,6</sup> Although no definitive associations have been found between MIH and maternal smoking, alcohol consumption, or specific illnesses during the third trimester, certain maternal medical conditions have been observed more frequently in children with MIH.<sup>3,6</sup> During the perinatal period, factors such as hypoxia, preterm birth, low birth weight, delivery complications, and cesarean section have been identified as contributors, with hypoxia demonstrating a particularly strong association.<sup>3,6</sup> In the postnatal period, environmental toxins, systemic illnesses, and especially antibiotic use during the first 4 years of life have been highlighted as key contributors.<sup>3,6</sup> Additionally, conditions such as measles, bronchitis, otitis, gastrointestinal and renal diseases, and asthma have been considered potential risk factors.<sup>3,6</sup> Genetic predisposition and epigenetic mechanisms may also influence the development of MIH by modulating gene expression in response to environmental exposures.<sup>6</sup>

Clinically, MIH is characterized by enamel defects accompanied by discoloration, ranging from opaque white to yellowish or brownish hues.<sup>7</sup> These color variations are determined by the degree of mineralization disturbance within the enamel. One of the most distinctive clinical features of MIH is the well-demarcated boundary opacities between affected and healthy enamel.<sup>1,3</sup> The severity of lesions varies, ranging from mild opacities to extensive structural breakdown.<sup>5</sup> Although the enamel initially forms with normal thickness, its hypomineralized nature renders it fragile and susceptible to fracture under masticatory forces, increasing the risk of dental caries. This often results in atypical restorations, progressive enamel breakdown, and, in severe cases, significant crown destruction requiring tooth extraction.<sup>3</sup>

Developmental enamel defects such as MIH should be evaluated not only for their biological and clinical implications but also for their negative impact on psychosocial well-being. Discoloration, opacities, and structural loss can lead to aesthetic concerns that adversely affect self-esteem and self-confidence, particularly during childhood and adolescence. These aesthetic issues may result in social withdrawal, increased susceptibility to peer bullying, and may negatively

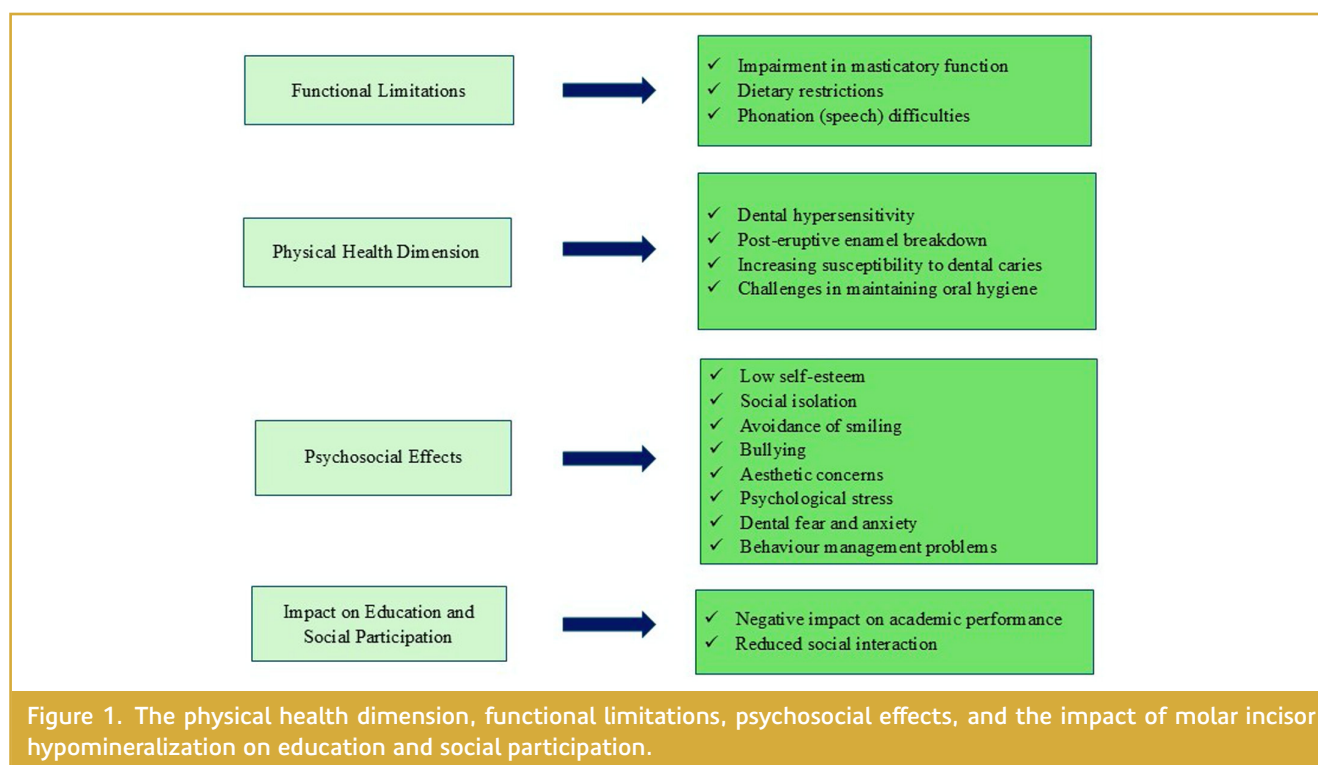
influence academic performance, personal development, and psychological health.<sup>8</sup> Furthermore, dental hypersensitivity and structural defects associated with MIH can contribute to speech impairments. Concerns about the aesthetic appearance of teeth may discourage individuals from smiling or speaking, potentially hindering their ability to form or maintain social connections.<sup>8</sup> (Figure 1)

This scoping review explores the impact of MIH-related pain, dentin hypersensitivity, aesthetic concerns, and functional impairments on individuals' daily lives. In addition, the psychosocial dimensions of MIH—including social isolation, peer bullying, and reduced self-confidence—are analyzed based on current scientific evidence. This framework highlights the importance of early diagnosis and individualized treatment strategies in improving oral health-related quality of life (OHRQoL). By presenting MIH not merely as a dental condition but as a multifactorial issue with psychosocial ramifications, this scoping review aims to enrich the existing literature and guide future research.

## SEARCH STRATEGY

In the present study, 4 electronic databases (PubMed, ScienceDirect, Google Scholar, and Scopus) were searched on October 1, 2024, by 2 pediatric dentists (T.A. and B.S.). The search was conducted using the following terms: molar incisor hypomineralization, molar incisor hypomineralisation, molar-incisor hypomineralization, molar-incisor hypomineralisation, demarcated opacities, post-eruptive enamel breakdown, MIH, quality of life, QoL, oral health related quality of life, OHRQoL, dental fear, dental anxiety, behavior management, esthetic concern, aesthetic concern, dental esthetic, dental aesthetic, bullying, and peer bullying. Only original research articles, case reports, and case series focusing on these topics were considered eligible. Systematic reviews and meta-analyses were excluded. Grey literature was not included in the scope of this review. Additionally, only articles written in English were included. The selection process involved screening titles and abstracts, and when necessary, reviewing full-text articles. A total of 32 articles were initially identified, of which 31 met the inclusion criteria. One article written in Spanish was excluded. The article selection process is illustrated in Figure 2 (PRISMA flowchart of the study selection process). The search strategy was framed based on the Population–Concept–Context framework:

- Population (P): Children and adolescents diagnosed with MIH;
- Concept (C): Psychosocial and behavioral outcomes associated with MIH, including pain, hypersensitivity, aesthetic concerns, functional impairments, OHRQoL, dental anxiety, behavior management issues, and peer bullying;
- Context (C): Clinical and community-based settings across various geographic regions, based on original research published in English between 2002 and 2024.



## SEARCH RESULTS

A total of 31 studies published between 2002 and 2024 were included in this review. The studies were conducted in a range of countries, including Germany, Brazil, Sweden, the United Kingdom, Nigeria, Mexico, Colombia, Egypt, Greece, Türkiye, and India, reflecting a geographically diverse research interest in the psychosocial and behavioral outcomes of MIH. The majority of the studies adopted a cross-sectional design, while others employed case-control, longitudinal, cohort, and in 1 instance, randomized clinical trial methodologies. The sample sizes varied considerably, ranging from single-case reports to large-scale investigations involving over 2000 children, with participants' ages spanning from 6 to 18 years. Molar incisor hypomineralization diagnosis was most frequently based on the European Academy of Paediatric Dentistry (EAPD) 2003 criteria. A variety of validated assessment tools were used to evaluate psychosocial and behavioral outcomes, including the Child Perceptions Questionnaire (CPQ in multiple age forms), the Child Oral Health Impact Profile (COHIP), the Children's Fear Survey Schedule–Dental Subscale (CFSS-DS), the Dental Anxiety Questionnaire (DAQ), and scales related to aesthetic perception. These instruments were applied to explore domains such as OHRQoL, dental fear and anxiety (DFA), behavioral management issues, aesthetic concerns, and experiences of peer bullying. Most studies focused on school-aged children, often assessing both children's and parents' perceptions of MIH-related impacts. Table 1 presents the authors, publication year, country, study design, sample characteristics, diagnostic criteria, assessment tools,

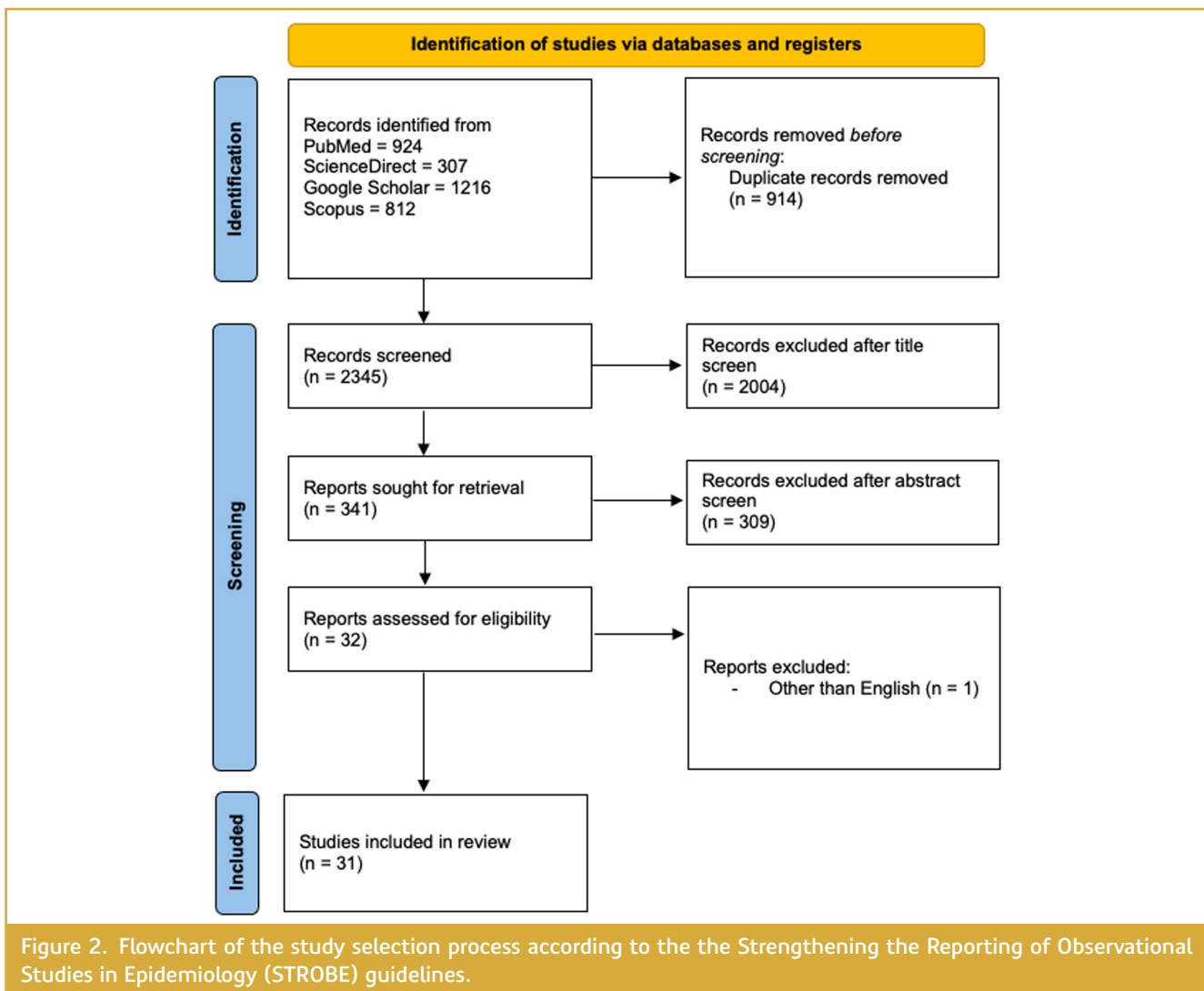
psychosocial or behavioral outcomes, and key findings evaluated in each included study.

## MOLAR INCISOR HYPOMINERALIZATION AND QUALITY OF LIFE

The World Dental Federation (FDI) defines oral health as a fundamental component of overall health and well-being, extending beyond the condition of the teeth and gums.<sup>9</sup> Oral health plays a crucial role in quality of life, social interaction, and psychological well-being. According to the FDI, oral health encompasses the ability to eat, speak, smile comfortably and without pain, contributing significantly to self-confidence and social participation. This holistic view highlights the physical, psychosocial, and functional dimensions of oral health, reinforcing its central role in overall quality of life.<sup>9</sup>

Quality of life is a multidimensional concept involving physical, mental, social, and emotional functioning. The World Health Organization (WHO) defines it as an individual's perception of their position in life, in the context of their culture, values, goals, expectations, and concerns.<sup>10</sup> Oral diseases and poor oral health can impair psychological well-being and social functioning, particularly during childhood, when dental appearance strongly influences emotional and social development.<sup>11</sup> Given this impact, researchers consider OHRQoL a comprehensive indicator of general health.<sup>12</sup>

As a developmental enamel defect, MIH results in both structural and aesthetic changes in the teeth, substantially



compromising OHRQoL. Affected teeth often exhibit hypersensitivity to thermal, chemical, and mechanical stimuli, leading many individuals to avoid brushing due to discomfort. This avoidance of oral hygiene increases the risk of dental caries, plaque accumulation, and periodontal disease.<sup>13,14</sup> Progressive enamel degradation and post-eruptive breakdown further exacerbate these issues, often requiring repeated and sometimes invasive dental treatments.<sup>3</sup>

In severe cases, the structural integrity of enamel is significantly compromised, affecting key oral functions such as mastication and speech. Reduced chewing efficiency may contribute to nutritional deficiencies, as individuals struggle to consume foods with certain textures. Consequently, this can result in poor nutrient intake and digestive problems.<sup>15</sup> Speech impairments caused by enamel damage and hypersensitivity can also hinder communication, potentially leading to social withdrawal and reduced self-esteem.<sup>16</sup>

Molar incisor hypomineralization has drawn increasing attention in clinical and academic settings due to its substantial impact on children's OHRQoL. A growing body of evidence, including systematic reviews, consistently shows that children with moderate to severe MIH report significantly lower OHRQoL compared to unaffected peers.<sup>5,11,12,14,17–19</sup> Common symptoms—such as hypersensitivity, pain, and functional limitations—can interfere with everyday activities like eating, speaking, or brushing, affecting not only oral health but also general well-being and self-confidence.<sup>11–13,17,20–23</sup> As MIH severity increases, these effects become more pronounced, leading to chewing difficulties, poor hygiene, and psychological distress.<sup>14,17</sup> Aesthetic concerns are especially common when anterior teeth are involved, prompting some children to avoid smiling or speaking in public.<sup>18,24</sup> These findings underscore that MIH is not only a physical condition but also a source of emotional and psychosocial burden.<sup>12,21,25</sup> Some studies report that MIH alone can reduce quality of life,<sup>11</sup> while others highlight a severity-dependent relationship with OHRQoL.<sup>14,19,26</sup>

Table 1. Author(s), Publication Year and Country, Study Design, Sample Size and Age Range, Diagnostic Criteria and Assessment Tools, Psychosocial/Behavioral Outcomes, and Key Findings of the 31 Articles Included in This Study

Study Number	Author(s)	Publication Year / Country	Study Design	Sample Size / Age Range	Diagnostic Criteria / Assessment Tools	Psychosocial/ Behavioral Outcomes	Key Findings
1	Reissenberger et al <sup>13</sup>	2022 / Germany	Cross-sectional study	252 children / 7–10 years	Mathu-Muju and Wright's classification / CPQ8–10	OHRQoL	The position of the MIH-affected teeth causes different influences on perceived OHRQoL.
2	Joshi et al <sup>14</sup>	2022 / Germany	Prospective case-control study	188 children / 8–10 years	EAPD (2003) criteria / CPQ8–10	OHRQoL	Children affected by MIH show an impaired OHRQoL compared to children without MIH; with increasing severity, OHRQoL gets more impaired.
3	Fragelli et al <sup>15</sup>	2021 / Brazil	Cross-sectional study	467 children / 8–12 years	EAPD (2003) criteria / Child Perception Questionnaire About Tooth Appearance (CQATA)	Aesthetic perception	Children with MIH showed more negative perceptions toward tooth health, tooth alignment, and tooth discoloration.
4	Leal et al <sup>16</sup>	2016 / Brazil	Case-control study	262 children / 7–13 years	EAPD (2003) criteria / Child and Parent Questionnaire About Tooth Appearance (CPQATA)	Perceived aesthetic and functional impact of MIH	Both children and mothers in the MIH group perceived MIH opacities negatively in comparison with controls.
5	Jälevik and Klingberg <sup>43</sup>	2012 / Sweden	Longitudinal case-control study	67 adolescents / 18 years	Not reported / CFSS-DS	Behavior management problems and DFA	Patients with severe MIH had a poorer dental health and more treatment consuming at age 18 years.
6	Jälevik and Klingberg <sup>20</sup>	2002 / Sweden	Case-control study	73 children / 9 years	Not reported / CFSS-DS	Behavior management problems and DFA	Children with severe enamel hypomineralization of their first molars had undergone a considerable amount of dental treatment.
7	Vanhée et al <sup>24</sup>	2022 / Belgium	Cross-sectional study	290 children / 8–9.5 years	Criteria / CFSS-DS, Child Oral Impacts on Daily Performances (C-OIDP)	Dental anxiety and OHRQoL	MIH had no significant impact on dental anxiety and OHRQoL in this population.
8	Dantas-Neta et al <sup>17</sup>	2016 / Brazil	Cross-sectional study	594 children / 11–14 years	EAPD (2003) criteria / Parental-Caregiver Perceptions Questionnaire (P-CPQ), CPQ11–14	OHRQoL and perception of children and parents	Schoolchildren with severe MIH had a greater negative impact on the oral symptom and functional limitation domains than those without MIH.
9	Dias et al <sup>21</sup>	2021 / Brazil	Cross-sectional study	253 children / 6–12 years	EAPD (2003) criteria / P-CPQ, CPQ8–10, CPQ11–14	OHRQoL and perception of children and parents	MIH promotes a negative impact on the OHRQoL. MIH had no significant impact on OHRQoL according to children's perceptions.
10	Gutiérrez et al <sup>25</sup>	2019 / Mexico	Cross-sectional study	411 children / 8–10 years	EAPD (2003) criteria / CPQ8–10	OHRQoL	Children with moderate/severe MIH experienced a greater negative impact on their OHRQoL compared to children without MIH.
11	Hasmun et al <sup>28</sup>	2020 / United Kingdom	Longitudinal cross-sectional study	86 children / 7–16 years	Not reported / COHIP-Short Form19 (SF19), Self-Perception Profile for Children (SPPC)	OHRQoL	Psychosocial factors and dental clinical characteristics were associated with change in children's OHRQoL following minimal interventions for incisor opacities.

(Continued)

Table 1. Author(s), Publication Year and Country, Study Design, Sample Size and Age Range, Diagnostic Criteria and Assessment Tools, Psychosocial/Behavioral Outcomes, and Key Findings of the 31 Articles Included in This Study (Continued)

Study Number	Author(s)	Publication Year / Country	Study Design	Sample Size / Age Range	Diagnostic Criteria / Assessment Tools	Psychosocial/ Behavioral Outcomes	Key Findings
12	Portella et al <sup>22</sup>	2021 / Brazil	Cross-sectional study	728 children / 8 years	EAPD (2003) criteria / CPQ8–10	OHRQoL	MIH considerably increases children's negative self-perceptions of oral symptoms, which include pain from dental origin.
13	Folayan et al <sup>23</sup>	2018 / Nigeria	Cross-sectional study	853 children / 6–16 years	EAPD (2003) criteria / C-OIDP	OHRQoL	MIH had no significant impact on the overall oral health quality of life of children in this study.
14	Velandia et al <sup>27</sup>	2021 / Colombia	Cross-sectional study	88 children / 7–10 years	EAPD (2003) criteria / CPQ8–10	OHRQoL	The presence of the MIH may have negative impact on the OHRQoL of the participating children.
15	Michaelis et al <sup>26</sup>	2021 / Germany	Case-control study	528 children / 7–10 years	EAPD (2003) criteria / CPQ8–10	OHRQoL	MIH showed a greater negative impact on OHRQoL.
16	Elhennawy et al <sup>18</sup>	2022 / Germany	Cross-sectional study	317 children / 7–14 years	EAPD (2003) criteria / COHIP–19	OHRQoL	MIH has a significant negative impact on the children's OHRQoL. Patients with severe MIH experience a greater negative impact on OHRQoL than those diagnosed with mild MIH.
17	Altner et al <sup>33</sup>	2022 / Germany	Case-control study	210 children / 7–11 years	EAPD (2003) criteria / CPQ8–10	OHRQoL	Patients with severe MIH experienced a greater overall improvement in OHRQoL compared to the caries group.
18	Gadallah et al <sup>19</sup>	2024 / Egypt	Case-control study	102 children / 8–10 years	EAPD (2003) criteria / CPQ8–10	OHRQoL	The presence of the severe form of MIH including hypersensitivity and enamel disintegration negatively impacted those children's OHRQoL.
19	Sekundo et al <sup>29</sup>	2024 / Germany	Cross-sectional study	35 children / 7–17 years	Not reported / COHIP–19	OHRQoL	Despite the high rate of restorative treatment with an acceptable failure rate, OHRQoL is reduced in children with MIH.
20	Fütterer et al <sup>30</sup>	2020 / Germany	Prospective cohort study	78 children / Not reported	EAPD (2003) criteria / CPQ11–14	OHRQoL	Therapy for affected teeth in children with MIH has positive effects on OHRQoL.
21	Tuğcu et al <sup>31</sup>	2022 / Türkiye	Cross-sectional study	78 children / 11–14 years	EAPD (2003) criteria / CPQ11–14	OHRQoL	Restorative treatment following selective caries removal positively influenced the OHRQoL of children with severe MIH.
22	Rodríguez et al <sup>40</sup>	2024 / Colombia	Cross-sectional study	159 children / 8–11 years	Criteria / CFSS-DS	DFA	Children with MIH exhibit higher levels of DFA than children without MIH.
23	Sezer et al <sup>36</sup>	2022 / Türkiye	Case-control study	127 children / 8–12 years	Criteria / CFSS-DS	DFA	There is no relation between the existence and severity of MIH and dental fear.
24	Menoncin et al <sup>41</sup>	2019 / Brazil	Cross-sectional study	731 children / 8 years	EAPD (2003) criteria / DAQ	DFA	The presence of MIH in schoolchildren was not associated with parental reports of dental anxiety.

(Continued)



Table 1. Author(s), Publication Year and Country, Study Design, Sample Size and Age Range, Diagnostic Criteria and Assessment Tools, Psychosocial/Behavioral Outcomes, and Key Findings of the 31 Articles Included in This Study (Continued)

Study Number	Author(s)	Publication		Study Design	Sample Size / Age Range		Diagnostic Criteria / Assessment Tools	Psychosocial/ Behavioral Outcomes	Key Findings
		Year / Country							
25	Kosma et al <sup>38</sup>	2016 / Greece		Cross-sectional study	2335 children / 8–14 years		EAPD (2003) criteria / CFSS-DS	DFA	A positive association between MIH and dental caries was confirmed and a lack of association found between MIH and dental fear.
26	Laureano et al <sup>39</sup>	2020 / Brazil		Cross-sectional study	466 children / 8–10 years		EAPD (2003) criteria / CFSS-DS	DFA	Dental caries and MIH were not associated with dental fear.
27	Large et al <sup>44</sup>	2020 / United Kingdom		Cross-sectional study	50 children / 7–16 years		EAPD (2003) criteria / COHIP-SF19	Aesthetic concerns	The first to look at concordance between what children feel about their opacities and what dentists are recording in their clinical assessment, are encouraging.
28	Athayde et al <sup>46</sup>	2024 / Brazil		Randomized clinical trial	39 children / 8–18 years		EAPD (2003) criteria / CPQATA	Aesthetic concerns	Aesthetic treatment of hypomineralization opacities in anterior teeth with resin infiltration impacted positively on parents and children.
29	Jaiswal et al <sup>47</sup>	2024 / India		Laboratory-based clinical study	50 children / 8–16 years		Criteria / Novel computerised assessment	Aesthetic concerns	The proposed approach exhibit sufficient quality to be integrated into a dental software addressing practical challenges encountered in daily clinical settings.
30	Oyedele et al <sup>45</sup>	2015 / Nigeria		Cross-sectional study	2107 children / Not reported		Criteria / Not reported	Aesthetic concerns	Children with MIH had more oral pathologies than children without MIH. These co-morbidities (dentine hypersensitivity, aesthetic concerns, caries and oral hygiene) are capable of impacting negatively on the quality of life of the children.
31	Scheffel et al <sup>49</sup>	2014 / Brazil		Case report	1 patient / 8 years		Not reported / Not reported	Peer bullying	Dental anomalies may be a motive for bullying.

CFSS-DS, Dental Subscale of the Children's Fear Survey Schedule; COHIP, Child Oral Health Impact Profile; C-OIDP, Child Oral Impacts on Daily Performance; CPQ, Child Perception Questionnaire; CPQATA, Child and Parent Questionnaire About Tooth Appearance; CQATA, Child Perceptions Questionnaire About Tooth Appearance; DAQ, Dental Anxiety Questionnaire; DFA, dental fear and anxiety; EAPD, European Academy of Paediatric Dentistry; MIH, molar incisor hypomineralization; OHRQoL, oral health-related quality of life; P-CPQ, Parental-Caregivers Perception Questionnaire; SF, Short Form; SPPC, Self Perception Profile for Children.<sup>1–2</sup>

Parental reports further support the psychosocial burden of MIH. Although younger children may struggle to articulate their discomfort, parents often notice emotional distress, reduced self-confidence, and social withdrawal.<sup>21</sup> These effects are more pronounced among children with concurrent dental caries or those from socioeconomically disadvantaged backgrounds.<sup>23,27</sup> Validated tools such as the CPQ8–10 and CPQ11–14, the C-OIDP, and the COHIP-SF have been widely used to assess OHRQoL in children with MIH. These tools consistently identify significant impacts in domains such as "oral symptoms" and "functional limitations."<sup>18,21,22,25</sup> As children grow older, the emotional and social dimensions of OHRQoL become more evident, especially regarding aesthetic concerns. Parent-reported tools such as the P-CPQ often show elevated scores in emotional well-being domains, reflecting parental awareness and concern.<sup>21</sup>

Encouragingly, several studies report that preventive and restorative treatments—such as fissure sealants, fluoride varnishes, glass hybrid restorations, microabrasion, resin infiltration, and composite restorations—can reduce hypersensitivity, improve aesthetics, and restore functionality, thereby positively influencing OHRQoL.<sup>28–31</sup> However, persistent issues such as enamel porosity and structural fragility continue to pose challenges for both clinicians and patients. These ongoing difficulties highlight the need for early diagnosis and the implementation of individualized, comprehensive, and long-term treatment strategies to support affected children's well-being and quality of life.<sup>29,32</sup>

Ultimately, the impairments associated with MIH can interfere with daily functioning and negatively impact both oral health and overall life satisfaction. In children and adolescents, the aesthetic implications often lead to reduced self-esteem, social withdrawal, and psychological distress. Studies have shown that MIH negatively affects OHRQoL regardless of severity, although the impact is more substantial in moderate to severe cases.<sup>17–19,25,33</sup> Despite these challenges, early diagnosis and timely treatment—such as sealants, microabrasion, resin infiltration, and composites—can alleviate symptoms and restore oral function and appearance. Adopting a multidisciplinary approach that combines prevention and restoration is essential for minimizing the negative consequences of MIH and improving the overall quality of life in affected individuals.

## **MOLAR INCISOR HYPOMINERALIZATION AND DENTAL FEAR, ANXIETY, AND BEHAVIOR MANAGEMENT CHALLENGES**

Dental fear refers to a reaction to a perceived threat, while dental anxiety describes the anticipatory apprehension experienced before a dental visit. In children, these emotional responses often overlap, prompting the use of the term DFA to describe the combined phenomenon. Dental fear and anxiety is considered multifactorial and is influenced by

psychological traits, previous experiences, the clinical setting, and sociocultural factors. Negative dental experiences can intensify these responses, and globally, pediatric DFA affects between 13.3% and 36.5% of children and adolescents.<sup>34</sup>

Children with MIH often exhibit heightened tooth sensitivity, leading to discomfort during oral hygiene practices and increased risk of caries and plaque accumulation.<sup>3</sup> Severe cases typically require more frequent and complex interventions and are associated with greater pain.<sup>35</sup> Even with adequate anesthesia, managing carious MIH-affected molars can be difficult due to persistent hypersensitivity.<sup>7</sup> Consequently, MIH has been considered a potential contributor to DFA and behavior management challenges.<sup>5</sup> However, existing evidence presents conflicting results regarding the direct association between MIH and elevated levels of DFA.

The majority of studies report no clear link between MIH and increased dental anxiety, even in severe cases.<sup>5,24,35–39</sup> A recent systematic review and meta-analysis confirmed this lack of association.<sup>35</sup> However, the same review noted that children with MIH are more likely to face behavioral difficulties during treatment, likely due to discomfort and the complexity of care. This suggests that although MIH may not directly trigger DFA, it can indirectly affect the child's experience by increasing treatment-related stress.

Additional studies have highlighted the impact of MIH on OHRQoL, primarily due to hypersensitivity and functional limitations.<sup>5</sup> While DFA is not always elevated, MIH can still shape children's perceptions of dental care, especially in cases involving repeated invasive procedures.<sup>35,36,38</sup> For example, children with active carious lesions in MIH-affected teeth may report more anxiety, particularly during treatment.<sup>40</sup>

Interestingly, most studies show no significant difference in DFA between children with mild versus severe MIH.<sup>36,41</sup> Previous painful experiences and the need for invasive procedures appear to be stronger predictors of DFA than the enamel defect itself. Furthermore, children without prior dental visits and girls consistently exhibit higher DFA levels, emphasizing the influence of experience and gender.<sup>24,38,39</sup>

Longitudinal studies indicate that DFA tends to decrease with age, likely due to increased exposure to oral health education and familiarity with dental care through school-based programs or family support.<sup>42</sup> However, MIH is associated with a higher clinical burden, with children often undergoing more frequent procedures—some without anesthesia—leading to distress or behavioral resistance.<sup>20</sup> These experiences may not be labeled as fear by the child but can shape long-term attitudes toward dental care. One follow-up study found that while anxiety levels normalized during adolescence, pain management difficulties and behavioral issues persisted.<sup>43</sup>

In summary, current evidence suggests that MIH alone does not directly cause elevated DFA.<sup>5,24,35,36,38,39,41</sup> Still, the



condition frequently coexists with pain, functional challenges, and behavior management difficulties. These factors can influence a child's perception of dental care and contribute to psychological distress. While the link between MIH and DFA remains inconclusive, clinicians should adopt empathetic and individualized treatment strategies, including preventive care and effective pain management, to reduce the emotional burden and support long-term well-being in children with MIH.

## MOLAR INCISOR HYPOMINERALIZATION AND AESTHETIC CONCERN AND BULLYING

Aesthetic perception plays a significant role in how individuals, particularly children, evaluate their dental appearance and overall self-image. Although subjective in nature, aesthetic perception is shaped by social norms, cultural expectations, and physical characteristics such as tooth color, alignment, and structural integrity.<sup>15</sup> In children with MIH, enamel opacities and discoloration—especially affecting the anterior teeth—can negatively impact self-perception and increase psychological distress.<sup>44</sup>

Molar incisor hypomineralization-related aesthetic concerns are particularly pronounced in children over the age of 9 and in cases involving multiple teeth.<sup>15,16</sup> These children often experience heightened self-awareness regarding visible enamel defects, leading to dissatisfaction with their dental appearance.<sup>16</sup> Studies using validated instruments such as the CPQATA consistently show that MIH-affected children report increased self-consciousness due to enamel discoloration and irregular tooth morphology.<sup>16,45</sup>

These aesthetic impairments may lead to reduced self-esteem, avoidance of smiling, and limited social engagement. Parents often perceive these concerns not merely as cosmetic but as significant factors affecting their child's emotional well-being.<sup>16</sup> Encouragingly, clinical interventions like resin infiltration have been shown to improve not only the visual appearance of teeth but also children's confidence in social settings.<sup>46</sup> Artificial intelligence-assisted digital analyses further confirm a correlation between the severity of enamel defects and dissatisfaction with dental appearance.<sup>47</sup>

In addition to aesthetic discomfort, MIH can increase vulnerability to peer bullying. Bullying—defined as persistent, intentional aggression marked by a power imbalance—can have serious psychosocial consequences.<sup>48,37</sup> Children with visible dental anomalies may be at greater risk of exclusion or ridicule.<sup>49,50</sup> Several reports have documented instances in which MIH-affected children exhibited low self-confidence and difficulty forming peer relationships, with bullying being a recurring theme.<sup>44</sup> Following aesthetic dental treatment, improvements have been noted not only in appearance but also in self-esteem, social participation, and academic performance.<sup>49</sup>

Despite these findings, the link between MIH and bullying remains underexplored. Existing studies tend to focus on appearance-related concerns, often neglecting deeper aspects such as the frequency, duration, and emotional impact of bullying.<sup>44,49</sup> Cultural influences and the perspectives of parents and teachers—who often witness these challenges—are also rarely addressed.

Future research should examine the broader psychosocial implications of MIH, with particular attention to bullying and social exclusion. Integrating children's voices into academic research can offer valuable insights into how these experiences shape emotional development. A deeper understanding of these dimensions will support more holistic clinical care and promote targeted strategies to address both functional and psychological needs.

## CONCLUSION

Molar incisor hypomineralization is more than a structural dental defect; it is a multifactorial condition with far-reaching implications for oral health, psychosocial development, and overall quality of life. The condition often results in dentin hypersensitivity, post-eruptive enamel breakdown, and aesthetic changes that compromise basic oral functions such as eating and speaking.

Achieving adequate local anesthesia in MIH-affected teeth is often challenging. Due to the increased sensitivity of hypomineralized tissues, children may experience more pain during dental procedures. These painful experiences not only complicate clinical management but can also lead to negative attitudes toward dental care. Therefore, adequate pain control in MIH cases is essential for both treatment success and long-term patient cooperation.

In children and adolescents, the presence of visible enamel defects frequently leads to emotional distress, reduced self-esteem, and social withdrawal. These effects highlight the need to recognize MIH not only as a clinical concern but also as a psychosocial issue. Additionally, the recurrent and sometimes invasive dental treatments required may foster negative attitudes toward dental care.

Given these complex challenges, early diagnosis and personalized treatment planning are essential. A holistic approach that integrates clinical management with psychological and social support can enhance long-term outcomes. Furthermore, incorporating MIH into broader public health frameworks may help optimize care strategies, raise awareness, and promote equity in access to treatment.

**Data Availability Statement:** The data that support the findings of this study are available on request from the corresponding author.

**Peer-review:** Externally peer-reviewed.

**Author Contributions:** Concept – T.A., B.S.; Design – T.A., B.S.; Supervision – B.S.; Resources – T.A., B.S.; Materials – T.A., B.S.; Data

Collection – T.A., B.S.; Analysis and/or Interpretation – T.A., B.S.; Literature Search – T.A., B.S.; Writing Manuscript – T.A.; Critical Review – B.S.

**Declaration of Interests:** The authors have no conflicts of interest to declare.

**Funding:** The authors declared that this study has received no financial support.

## REFERENCES

- Weerheijm KL, Jälevik B, Alaluusua S. Molar-incisor hypomineralisation. *Caries Res.* 2001;35(5):390–391. [\[CrossRef\]](#)
- Lopes LB, Machado V, Mascarenhas P, Mendes JJ, Botelho J. The prevalence of molar-incisor hypomineralization: a systematic review and meta-analysis. *Sci Rep.* 2021;11(1):22405. [\[CrossRef\]](#)
- Lygidakis NA, Garot E, Somani C, Taylor GD, Rouas P, Wong FSL. Best clinical practice guidance for clinicians dealing with children presenting with molar-incisor-hypomineralisation (MIH): an updated European Academy of Paediatric Dentistry policy document. *Eur Arch Paediatr Dent.* 2022;23(1):3–21. [\[CrossRef\]](#)
- Koch G, Hallonsten AL, Ludvigsson N, Hansson BO, Holst A, Ullbro C. Epidemiologic study of idiopathic enamel hypomineralization in permanent teeth of Swedish children. *Community Dent Oral Epidemiol.* 1987;15(5):279–285. [\[CrossRef\]](#)
- Jälevik B, Sabel N, Robertson A. Can molar incisor hypomineralization cause dental fear and anxiety or influence the oral health-related quality of life in children and adolescents? A systematic review. *Eur Arch Paediatr Dent.* 2022;23(1):65–78. [\[CrossRef\]](#)
- Garot E, Rouas P, Somani C, Taylor GD, Wong F, Lygidakis NA. An update of the aetiological factors involved in molar incisor hypomineralisation (MIH): a systematic review and meta-analysis. *Eur Arch Paediatr Dent.* 2022;23(1):23–38. [\[CrossRef\]](#)
- Vicioni-Marques F, Paula-Silva FWG, Carvalho MR, et al. Preemptive analgesia with ibuprofen increases anesthetic efficacy in children with severe molar: a triple-blind randomized clinical trial. *J Appl Oral Sci.* 2022;30:e20210538. [\[CrossRef\]](#)
- Walia T. MIH-impact on public health and children's oral health-related quality of life. *Oralprophylaxe Kinderzahnmed.* 2024;46:284–287.
- FDI World Dental Federation. FDI's definition of Oral Health. Available at: <https://www.fdiworldental.org/fdis-definition-or-al-health>. Accessed March 17, 2025.
- The World Health Organization. The World Health Organization Quality of Life assessment (WHOQOL): position paper from the World Health Organization. *Soc Sci Med.* 1995;41(10):1403–1409. [\[CrossRef\]](#)
- Amrollahi N, Hashemi S, Heidari Z. Impact of molar incisor hypomineralization on oral health-related quality of life in 8–10 years old children: a systematic review and meta-analysis. *J Evid Based Dent Pract.* 2023;23(3):101889. [\[CrossRef\]](#)
- Jawdekar AM, Kamath S, Kale S, Mistry L. Assessment of oral health-related quality of life (OHRQoL) in children with molar incisor hypomineralization (MIH): a systematic review and meta-analysis of observational studies. *J Indian Soc Pedod Prev Dent.* 2022;40(4):368–376. [\[CrossRef\]](#)
- Reissenberger T, Ebel M, Klode C, Hirsch C, Bekes K. Hypomineralized teeth and their impact on Oral-Health-related quality of life in primary school children. *Int J Environ Res Public Health.* 2022;19(16):10409. [\[CrossRef\]](#)
- Joshi T, Rahman A, Rienhoff S, Rienhoff J, Stamm T, Bekes K. Impact of molar incisor hypomineralization on oral health-related quality of life in 8–10-year-old children. *Clin Oral Invest.* 2022;26(2):1753–1759. [\[CrossRef\]](#)
- Fragelli C, Barbosa TS, Bussaneli DG, Restrepo M, Cordeiro RCL, Santos-Pinto L. Aesthetic perception in children with molar incisor hypomineralization. *Eur Arch Paediatr Dent.* 2021;22(2):227–234. [\[CrossRef\]](#)
- Leal SC, Oliveira TRM, Ribeiro APD. Do parents and children perceive molar-incisor hypomineralization as an oral health problem? *Int J Paediatr Dent.* 2017;27(5):372–379. [\[CrossRef\]](#)
- Dantas-Neta NB, Moura LF, Cruz PF, et al. Impact of molar-incisor hypomineralization on oral health-related quality of life in schoolchildren. *Braz Oral Res.* 2016;30(1):e117. [\[CrossRef\]](#)
- Elhennawy K, Rajjoub O, Reissmann DR, et al. The association between molar incisor hypomineralization and oral health-related quality of life: a cross-sectional study. *Clin Oral Invest.* 2022;26(5):4071–4077. [\[CrossRef\]](#)
- Gadallah LK, Korayem E, Wahby R. Oral Health-related quality of life in Egyptian children with molar incisor hypomineralisation: an observational study. *BDJ Open.* 2024;10(1):89. [\[CrossRef\]](#)
- Jälevik B, Klingberg GA. Dental treatment, dental fear and behaviour management problems in children with severe enamel hypomineralization of their permanent first molars. *Int J Paediatr Dent.* 2002;12(1):24–32.
- Dias FMCS, Gradella CMF, Ferreira MC, Oliveira LB. Molar-incisor hypomineralization: parent's and children's impact perceptions on the oral health-related quality of life. *Eur Arch Paediatr Dent.* 2021;22(2):273–282. [\[CrossRef\]](#)
- Portella PD, Menoncin BLV, de Souza JF, de Menezes JVN, Fraiz FC, Assunção LRDS. Impact of molar incisor hypomineralization on quality of life in children with early mixed dentition: a hierarchical approach. *Int J Paediatr Dent.* 2019;29(4):496–506. [\[CrossRef\]](#)
- Folayan MO, Chukwumah NM, Popoola BO, et al. Developmental defects of the enamel and its impact on the oral health quality of life of children resident in Southwest Nigeria. *BMC Oral Health.* 2018;18(1):160. [\[CrossRef\]](#)
- Vanhée T, Poncelet J, Cheikh-Ali S, Bottenberg P. Prevalence, caries, dental anxiety and quality of life in children with MIH in Brussels, Belgium. *J Clin Med.* 2022;11(11):3065. [\[CrossRef\]](#)
- Gutiérrez TV, Ortega CCB, Pérez NP, Pérez AG. Impact of molar incisor hypomineralization on oral health-related quality of life in Mexican schoolchildren. *J Clin Pediatr Dent.* 2019;43(5):324–330. [\[CrossRef\]](#)
- Michaelis L, Ebel M, Bekes K, Klode C, Hirsch C. Influence of caries and molar incisor hypomineralization on oral health-related quality of life in children. *Clin Oral Invest.* 2021;25(9):5205–5216. [\[CrossRef\]](#)
- Velandia LM, Álvarez LV, Mejía LP, Rodríguez MJ. Oral Health-related quality of life in Colombian children with molar-incisor hypomineralization. *Acta Odontol Latinoam.* 2018;31(1):38–44.
- Hasmun N, Vettore MV, Lawson JA, Elcock C, Zaitoun H, Rodd HD. Determinants of children's oral health-related quality of life following aesthetic treatment of enamel opacities. *J Dent.* 2020;98:103372. [\[CrossRef\]](#)

29. Sekundo C, Jung M, Muscholl C, Frese C. Oral Health-related quality of life and survival analysis after preventive and restorative treatment of molar-incisor hypomineralisation. *Sci Rep*. 2024;14(1):777. [\[CrossRef\]](#)
30. Fütterer J, Ebel M, Bekes K, Klode C, Hirsch C. Influence of customized therapy for molar incisor hypomineralization on children's oral hygiene and quality of life. *Clin Exp Dent Res*. 2020;6(1):33–43. [\[CrossRef\]](#)
31. Tuğcu N, Sezer B, Çalışkan C, Durmuş B, Kargül B. Changes in oral health-related quality of life after treatment of molar incisor hypomineralisation using glass hybrid restorations. *J Pak Med Assoc*. 2022;72(10):1977–1982. [\[CrossRef\]](#)
32. Bekes K, Amend S, Priller J, Zamek C, Stamm T, Krämer N. Hypersensitivity relief of MIH-affected molars using two sealing techniques: a 12-week follow-up. *Clin Oral Investig*. 2022;26(2):1879–1888. [\[CrossRef\]](#)
33. Altner S, Ebel M, Ritschl V, Stamm T, Hirsch C, Bekes K. Treatment of severe caries and molar incisor hypomineralization and its influence on oral health-related quality of life in children: a comparative study. *Int J Environ Res Public Health*. 2022;19(5):2983. [\[CrossRef\]](#)
34. Grisolia BM, Dos Santos APP, Dhyppolito IM, Buchanan H, Hill K, Oliveira BH. Prevalence of dental anxiety in children and adolescents globally: a systematic review with meta-analyses. *Int J Paediatr Dent*. 2021;31(2):168–183. [\[CrossRef\]](#)
35. Reis PPG, Jorge RC, Ferreira DMTP, Marañón-Vásquez GA, Maia LC, Soviero VM. Do patients with molar incisor hypomineralization have more dental anxiety and behavior management problems? A systematic review with meta-analysis. *Braz Oral Res*. 2023;37:e069. [\[CrossRef\]](#)
36. Sezer B, Tuğcu N, Çalışkan C, Durmuş B, Kargül B. Assessment of dental fear in children with molar-incisor hypomineralization. *J Stomatol*. 2022;75(2):107–114. [\[CrossRef\]](#)
37. Dubey VP, Kievišienė J, Rauckiene-Michealsson A, Norkiene S, Razbadauskas A, Agostinis-Sobrinho C. Bullying and health-related quality of life among adolescents: a systematic review. *Children (Basel)*. 2022;9(6):766. [\[CrossRef\]](#)
38. Kosma I, Kevrekidou A, Boka V, Arapostathis K, Kotsanos N. Molar incisor hypomineralisation (MIH): correlation with dental caries and dental fear. *Eur Arch Paediatr Dent*. 2016;17(2):123–129. [\[CrossRef\]](#)
39. Laureano ICC, Farias L, Fernandes LHF, et al. Dental fear in children: association with dental caries and molar incisor hypomineralization. *Braz Dent J*. 2020;31(6):673–679. [\[CrossRef\]](#)
40. Rodríguez ÓA, Laverde M, Rojas-Gualdrón DF, et al. The level of dental fear and anxiety is higher in children with both severe molar-incisor hypomineralisation and active dental caries lesions compared to children without these conditions. *Eur Arch Paediatr Dent*. 2024;25(5):655–662. [\[CrossRef\]](#)
41. Menoncin BLV, Portella PD, Ramos BLM, Assunção LRDS, De Souza JF, Menezes JVNB. Dental anxiety in schoolchildren with molar incisor hypomineralization: a population-based cross-sectional study. *Int J Paediatr Dent*. 2019;29(5):615–623. [\[CrossRef\]](#)
42. Gao S, Lu J, Li P, Yu D, Zhao W. Prevalence and risk factors of children's dental anxiety in China: a longitudinal study. *BMJ Open*. 2021;11(4):e043647. [\[CrossRef\]](#)
43. Jälevik B, Klingberg G. Treatment outcomes and dental anxiety in 18-year-olds with MIH, comparisons with healthy controls: a longitudinal study. *Int J Paediatr Dent*. 2012;22(2):85–91. [\[CrossRef\]](#)
44. Large JF, Hasmun N, Lawson JA, Elcock C, Vettore MV, Rodd HD. What children say and clinicians hear: accounts relating to incisor hypomineralisation of cosmetic concern. *Eur Arch Paediatr Dent*. 2020;21(2):185–191. [\[CrossRef\]](#)
45. Oyedele TA, Folayan MO, Adekoya-Sofowora CA, Oziegbe EO. Co-morbidities associated with molar-incisor hypomineralisation in 8 to 16 year old pupils in Ile-Ife, Nigeria. *BMC Oral Health*. 2015;15:37. [\[CrossRef\]](#)
46. Athayde GDS, Reis PPGD, Jorge RC, Americano GCA, Fidalgo TKDS, Soviero VM. Impact of masking hypomineralization opacities in anterior teeth on the esthetic perception of children and parents: a randomized controlled clinical trial. *J Dent*. 2022;123:104168. [\[CrossRef\]](#)
47. Jaiswal M, Mukhtar U, Shakya KS, Laddi A, Singha LA. Computerised assessment—a novel approach for calculation of percentage of hypomineralized lesion on incisors and its correlation with aesthetic concern. *J Oral Biol Craniofac Res*. 2024;14(5):570–577. [\[CrossRef\]](#)
48. Albaladejo-Blázquez N, Ferrer-Cascales R, Ruiz-Robledillo N, et al. Health-related quality of life and mental health of adolescents involved in school bullying and homophobic verbal content bullying. *Int J Environ Res Public Health*. 2019;16(14):2622. [\[CrossRef\]](#)
49. Scheffel DLS, Jeremias F, Fragelli CMB, Dos Santos-Pinto LAM, Hebling J, de Oliveira OB Jr. Esthetic dental anomalies as motive for bullying in schoolchildren. *Eur J Dent*. 2014;8(1):124–128. [\[CrossRef\]](#)
50. Sezer B, Akbaş ZS, Kara AT. The influence of molar incisor hypomineralization-related enamel defects in anterior teeth on peer perception of smile esthetics in children and adolescents. *J Dent*. 2025;163:106117. [\[CrossRef\]](#)